Book Reviews

© 2024 Fondazione Vasculab impresa sociale ONLUS. All rights reserved.

The 3 atlas-books of venous anatomy by Uhl and Gillot

Methods and results

JP Benigni

Sorbonne Université Faculté de Médecine Campus Pitiè-Salpetrière

submitted: Feb 8, 2024, , EPub Ahead of Print: Apr 28, 2024, published: Apr 30, 2024
Conflict of interest: None

DOI: 10.24019/jtavr.187 - Corresponding author: Dr. Jean-Patrick Benigni, benigni.jp@orange.fr

© 2024 Fondazione Vasculab impresa sociale ONLUS. All rights reserved.

Keywords venous anatomy, dissection, CT venography, Embryogenesis, 3D modeling

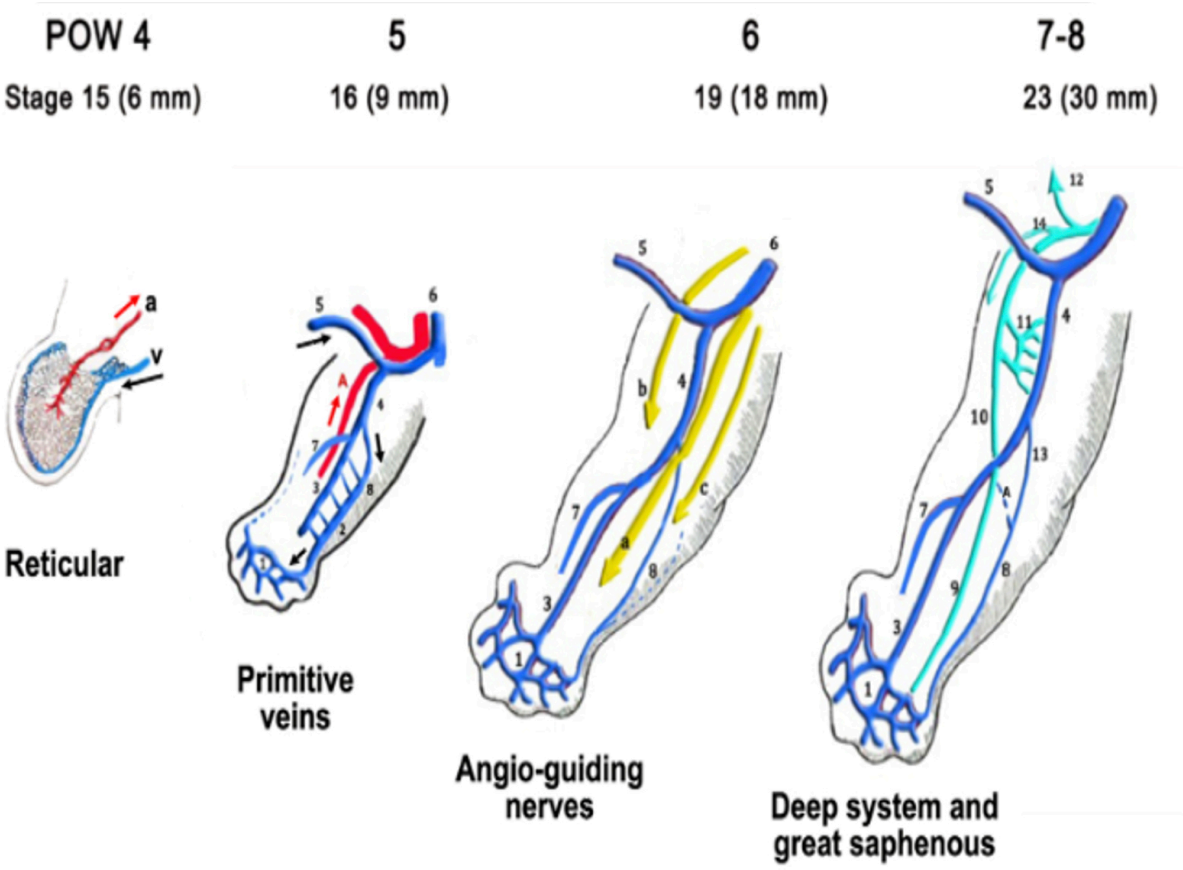

Figure 1 - Organogenesis period of development1 (weeks 4 to 8 – Carnegie stages 12-23)

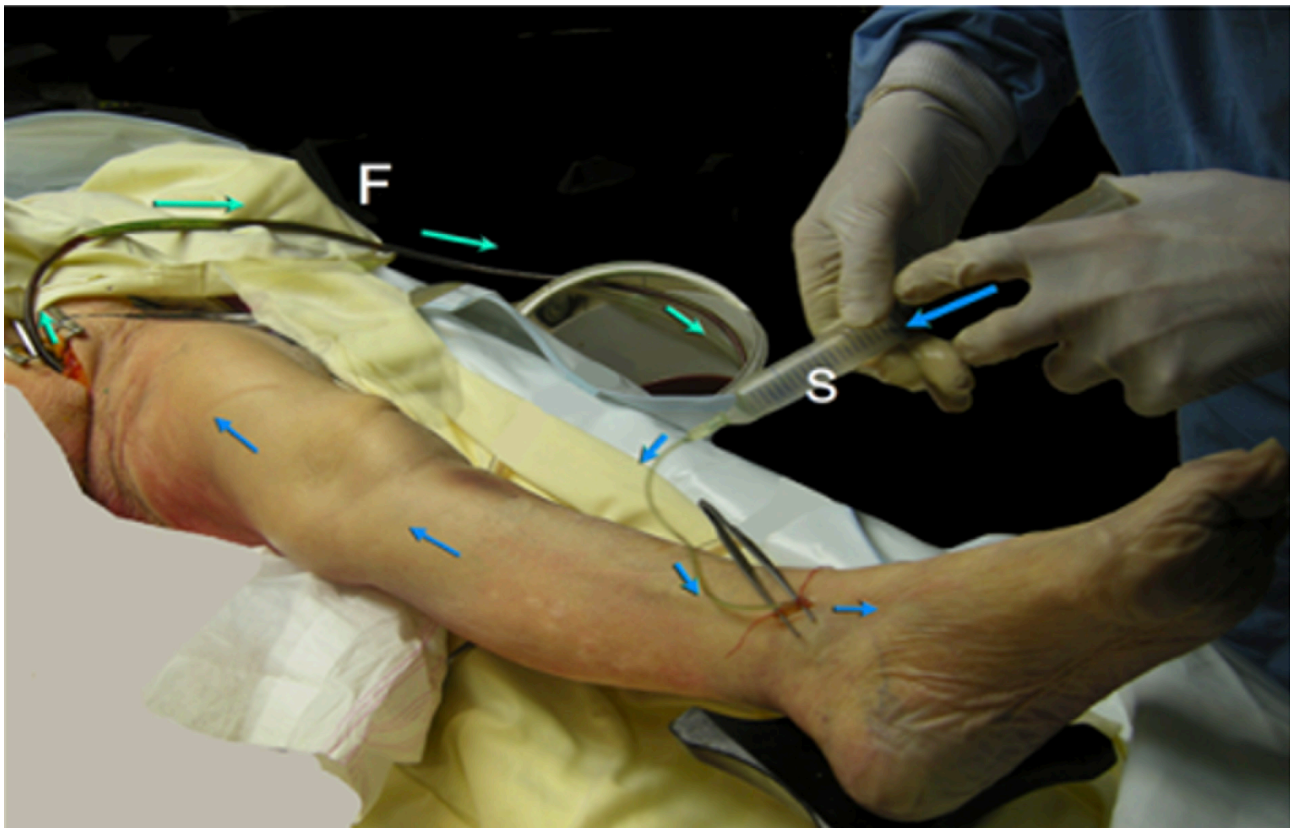

Figure 2 - Washing of the venous system



Figure 3 - Latex injection

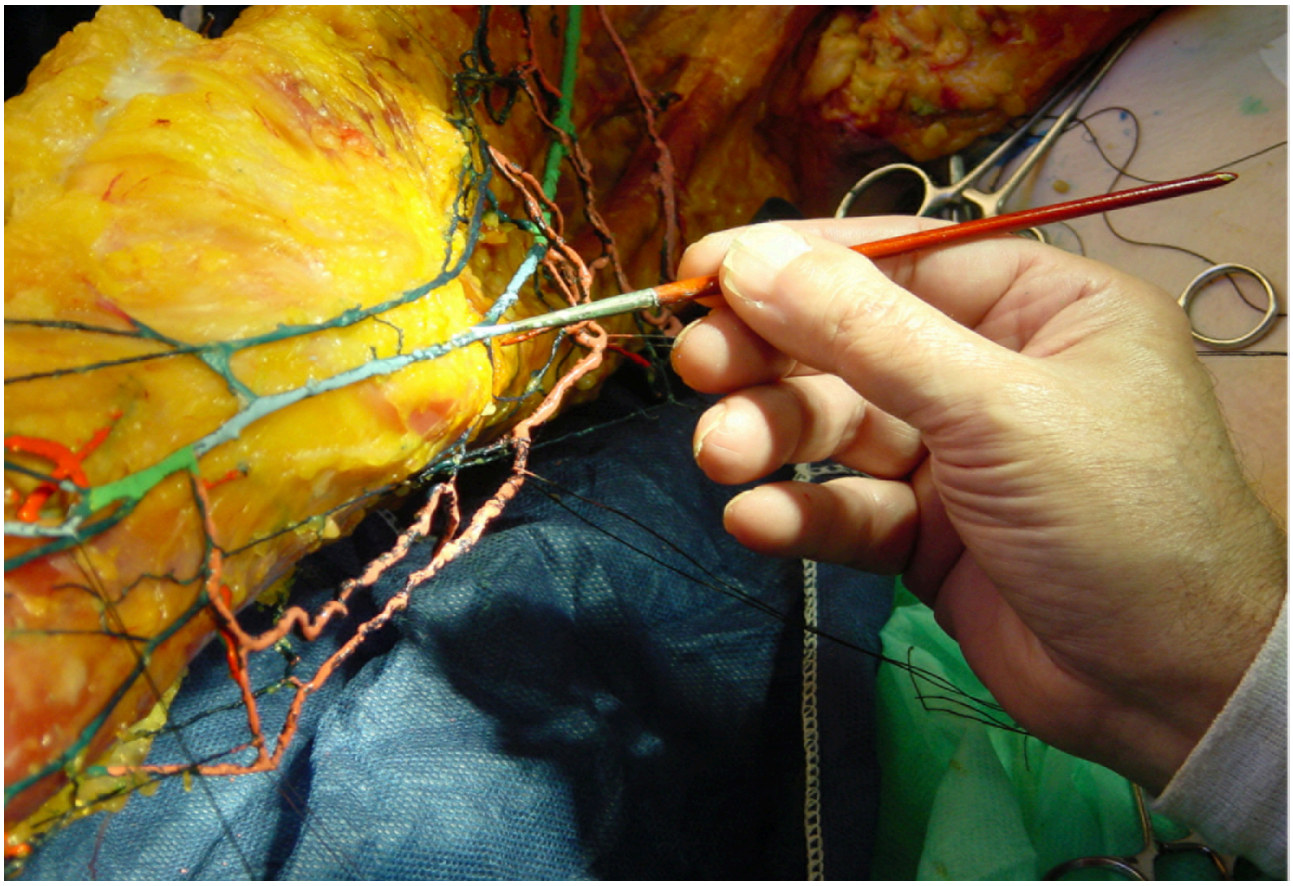

Figure 4 - Colored segmentation by painting of the veins after dissection

Anatomy is a basic, unavoidable, science for every physician and particularly for surgeons. Being especially variable and complex, human venous system has not been accurately described in main anatomy books.

Cadaveric anatomical dissection still remains the main source of knowledge about human anatomy, in particular for the veins, which are the more complex anatomy of the body. Based upon Prof. Claude Gillot's **technique of color segmentation** transforming complex venous networks into easy understandable morphological information, this book is solid proof of the educational value of his technique.

In addition, new digital tools are increasingly available, rapidly evolving our approach to human anatomy understanding, enabling easier access to both interpretation and recalling of venous anatomy variability and intricacy. For this reason, these books widely use 3D anatomical models for CT-venography from venous patients.

From a large amount of information, collected over 25 years joining Prof. Gillot's work, contents of this books came from the following sources:

- Anatomical dissections, after latex injection, of more than 400 limbs;
- 3D reconstructions from CT venography of 1.200 limbs;
- Pre-surgical skin venous mapping of 25.000 limbs.

The aim of this books is to focus on common and practical anatomical facts, to assist radiologists, sonographers, surgeons, phlebologists and anatomists on their daily practice.

1. Reminder of embryogenesis of the venous system

The primitive venous system of the lower limb appears between weeks 5 and 6 of the embryo's development (figure 1)[1,2]. The marginal vein and the small saphenous vein appear superficially. They originate from the primitive sciatic vein, then from the axial system, and then from the primitive peroneal vein.

The second stage occurs between weeks 7 and 8, following the appearance of the angio-guiding nerves (end of week 6) by maturation of the three plexuses along the angio-guiding nerves; the femoral vein, the great saphenous

vein, and the posterior tibial veins appear. Anastomoses between the 3 plexuses also will give origin to the popliteal crossroad, the sapheno-popliteal junction, and the Giacomini vein. This is achieved during the **organogenesis period** which provides the maturation of the veins along the 3 angio-guiding nerves (figure 1)

Finally, the fetal period (after 8 weeks) provides the final anatomy. At that time, the main venous axis of the thigh is a big axial vein, which will become hypoplastic as a small arcade along the sciatic nerve in 90% of the adults while the femoral vein remains as the main trunk of the thigh.

This explains the duplication of the femoral vein[3] in about 10% of adults.

2. Method of anatomical dissection with colored segmentation of the venous system

Lower limbs preparation[4]

Fresh cadavers are provided by the Centre du Don des Corps (Descartes University of Paris), and the procedure is as follows:

- Incision of the great saphenous vein at the ankle. Introduction of a butterfly 19-gauge catheter downwards, in the opposite direction of venous return;
- Common femoral vein approach through vertical incision. Insertion of a plastic cannula (C) to drain out the washing fluid, which will be injected from the ankle (figure 2);
- Irrigation of the foot with soapy water, to remove blood and thrombi from the venous system, until a clear washing fluid is obtained;
- Soapy water is then injected with low pressure, using a 20 ml plastic syringe (S), until a clear fluid is drained through the femoral (F) exit-cannula;
- A massage of the leg and thigh muscles is then performed, in order to wash out remaining blood and thrombi. This procedure must be repeated 2-4 times, until the drained fluid is completely clear.

Green latex injection

After removal of the draining cannula and ligation of the femoral vein, previously filtered green latex is slowly injected through the saphenous catheter using a 20 ml plastic syringe (figure 3). To fill the superficial venous system, a total volume of 120 to 150 ml is injected in each limb. The whole procedure takes about 30 minutes and is completed once the femoral vein has been filled with latex. If a leaking point appears somewhere, a simple compression maneuver should close it.

Anatomical dissection becomes possible one day after latex injection, being skin ablation its first step.

Painting of the veins: After anatomical dissection and identification, the painting of the veins helps to easily identify the elements of the network. This is called the technique of "colored segmentation". Here, on the figure 4, the right GSV is colored in light blue.

3. Methods of 3D modeling of the veins from CT-venography

[5-33]Summary of Spiral CT principle:

Multi-slice spiral or helical CT scanners combine 2 different movements (Figure 5). On one hand, the rotation around the scanning table of an energy source or emitter (the X ray tube) attached to detectors of that energy (receiver) located on the opposite side of the patient. On the other hand, a continuous displacement of the scanning table. During a complete rotation of the X ray tube, multiple snapshots collected by the receiver are sent to the scanner's computer, which creates a highly detailed cross-sectional image of a thin slice of the body. The table is then automatically displaced to the next scanning position and the whole cycle starts again: each time the table moves, the scanner will circle again. The sequence displacement/ rotation will be repeated, with an image slice being created at each position, until the full length of the targeted body segment has been scanned.

Technique and protocol:

Direct CTV is performed injecting radiological contrast through a vein of the dorsal foot, whereas indirect CTV is obtained by injecting a vein of the forearm. The latter technique requires CT image acquisition to be delayed, until the opacified contrast column has reached the venous phase.

Precise contrast media delivery is achieved using an automatic programmable CT injection system. For direct CTV, the intravenous iodinated contrast agent is diluted 10 times, and injected with a flow-rate of 2 to 5 cc per second.

Images are obtained commonly using CT scanners of 64 or 128 rows of detectors. Acquisition starts 30 seconds after the beginning of the injection, in ascending direction from the feet up to groin (or the diaphragm if necessary). Acquisition duration is about 20 to 40 seconds. Scanning parameters protocols for CTV are described in Table I.

TABLE I: MULTISLICE SPIRAL CT PROTOCOLS FOR CT VENOGRAPHY.

Protocols	Acquisition	Reconstruction	Postprocessing	Contrast injection
16 detectors CT: 600 slices in 25 s	120 kV, 150 mAs, slice collimation: 16 × 1.5 mm field 512, F.O.V 380 mm	Slice width 2 mm, slice increment 1.5 mm, filter B30 matrix 512 × 512, zoom factor 1.7	1998–2012 Volume rendering (VRT) fast and automatic with tissues transparencies	Medrad MCT injector system Uni-phasic injection 20 mL of iodine contrast medium in 180 mL of serum
64 detectors, CT: 1000 slices in 20 s	120 kV, 150 mAs	slice width 1 mm, slice increment 0.75 mm, matrix 512 × 512, zoom factor 1.7	VRT	Puncture of a vein of the dorsal foot or scarcely the varices of the thigh
128 detectors, MDCT: 1000 slices in 10 s		Rotation time 300 ms using a continuous helical scan mind-ose® technique pitch = 0.16–0.22	VRT with PC using multiprocessors Osirix using fast graphic card	Proximal injection and biphasic injection to visualize pelvic veins

CT, computed tomography; VRT, Volume rendering technique; MDCT, multidector computed tomography; MCT, multislice CT (MSCT)

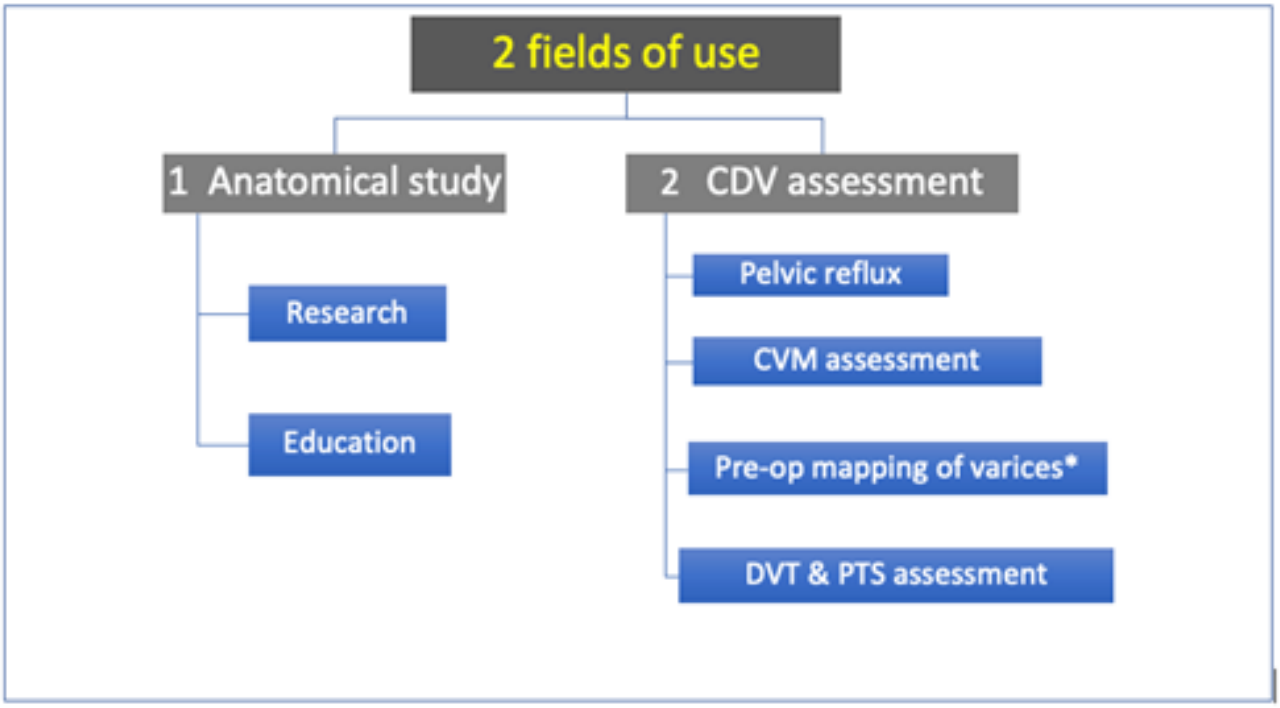

*Table II - 1) allows 3D interactive virtual dissection of the limb; 2) is pure morphological information, therefore DUS is mandatory for hemodynamical assessment. * Particularly for REVAS, complex cases and popliteal fossa recurrence.*

An average of over 1.000 radiological images are obtained in one single acquisition.

3D reconstruction from direct Volume Rendering Technique (VRT) is possible using dedicated software (3Dslicer®, Horos®, Vitrea ®, Siemens, GE, Toshiba), either with the scanner's work station or a personal computer (figure 5). The creation of rotational movies is possible as well, and a virtual dissection of the body region under study.

Advantages of 3D reconstruction from direct CVT:

- Overall assessment of superficial, deep and perforating systems morphology.
- Accurate 3D information

- Quick and interactive viewing of anatomical structures.
- 3D anatomical mapping in addition to the hemodynamic ultrasound venous mapping.

Disadvantages: CTV requires contrast media injection. Since it provides morphological information only, color Doppler ultrasound functional evaluation (venous hemodynamic mapping: VHM) is needed to complete a proper assessment.

Additional techniques can be used to improve results. Patients are often asked to perform a Valsalva maneuver, aimed to achieve better filling of pelvic veins while searching for reflux leaking points. During CT image acquisition, an inflated balloon may be held at the umbilical region instead, with the same above-mentioned goal.

Tourniquet use is advisable, and its location depends on the body segment to be studied. It is usually placed above the ankle, to force opacified flow towards deep venous system.

If the intention was to assess the popliteal and femoral vein, it is placed at the upper thigh.

Main fields of use of CT-venography (CTV)

Indications[5-33] for education, research and patient´s assessment purposes (table II)

Educational use of 3D modeling:

- CTV is both a great educational tool to learn venous anatomy and a powerful research tool to improve our understanding of the venous system.
- Building of interactive animations, rotational models and journeys inside the body.
- Allows a virtual dissection of the limb
- 3D printing of anatomical models of anatomical variations

Working methodology and 3D printing:

To create models from CTV Dicom files, we follow the 3 following steps, using available free software :

- 3Dslicer[34] to build mesh models with anatomical segmentation.
- Meshmixer[35] to clean, simplify and repair the 3D mesh files.
- Cura[36] dedicated to the 3D printing of the models.

Courses and workshops are regularly organized to promote these new educational tools in the frame of the Unesco Chair of Digital Anatomy (Paris cité University).

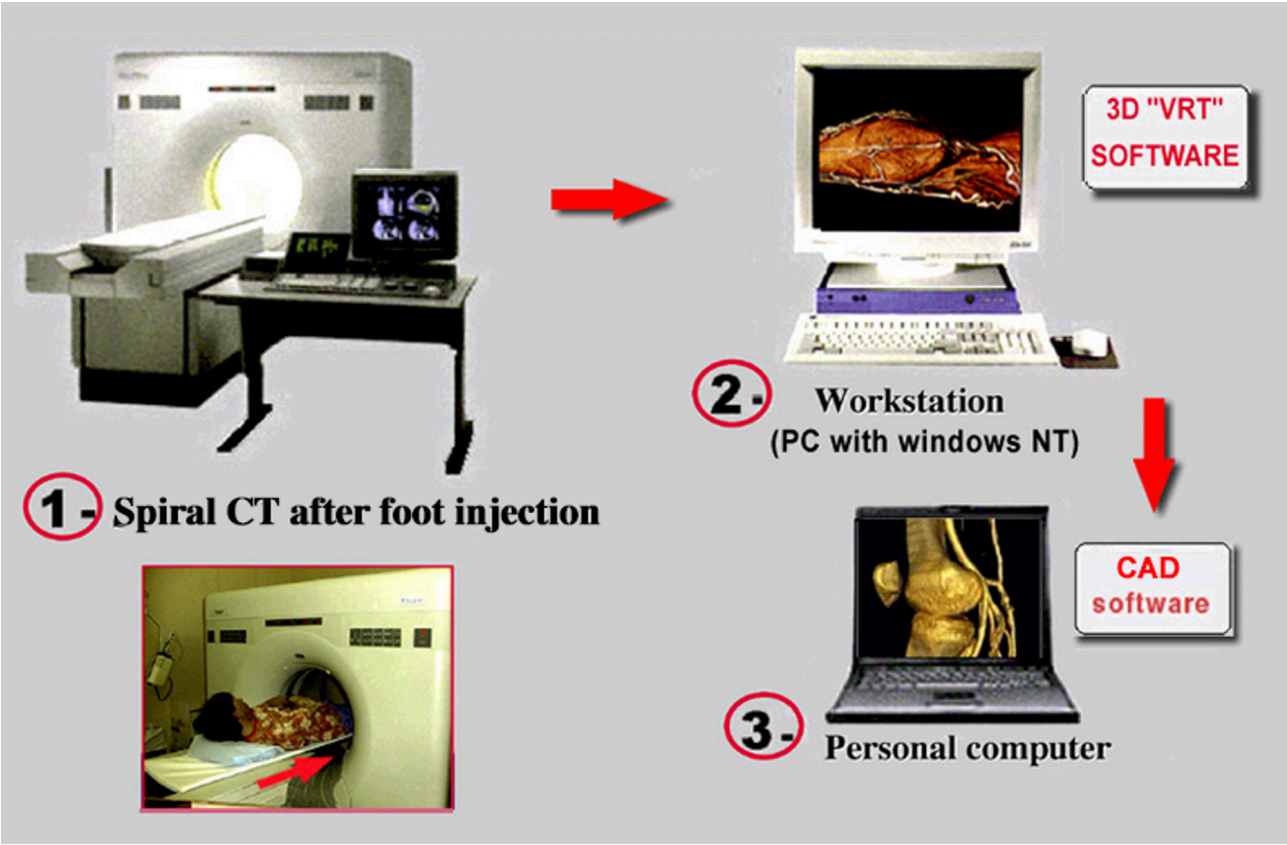

Figure 5 - 3D reconstruction of the anatomy by volume rendering technique.

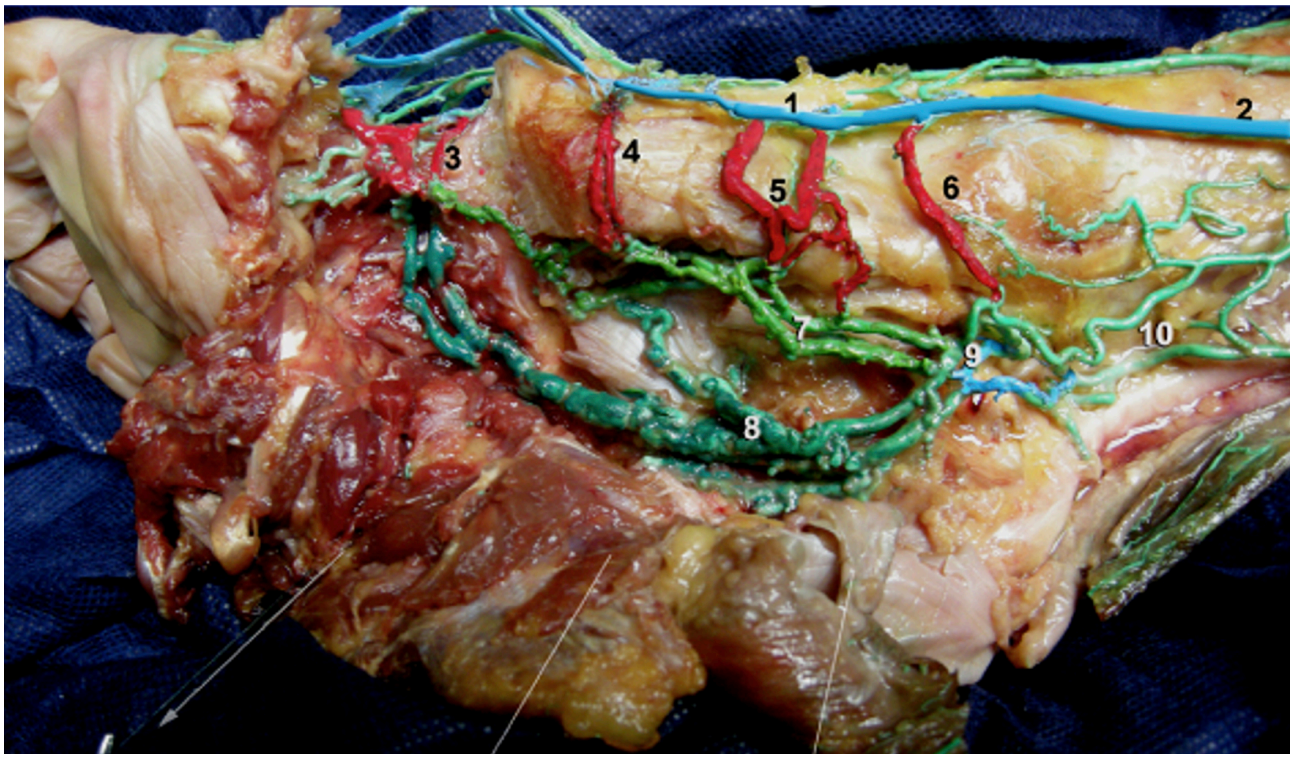

Figure 6A - Anatomical dissection after latex injection of the plantar veins. (right foot) The two plantar veins (medial view after resection of the first metatarsal bone). 1= medial marginal vein 2= GSV 3= perforator of the first metatarsal interspace 4= cuboidian PV 5= navicular perforator 6= inframalleolar PV 7= medial plantar veins (light green) 8= lateral plantar veins (dark green) 9= calcaneal plexus 10= PT veins

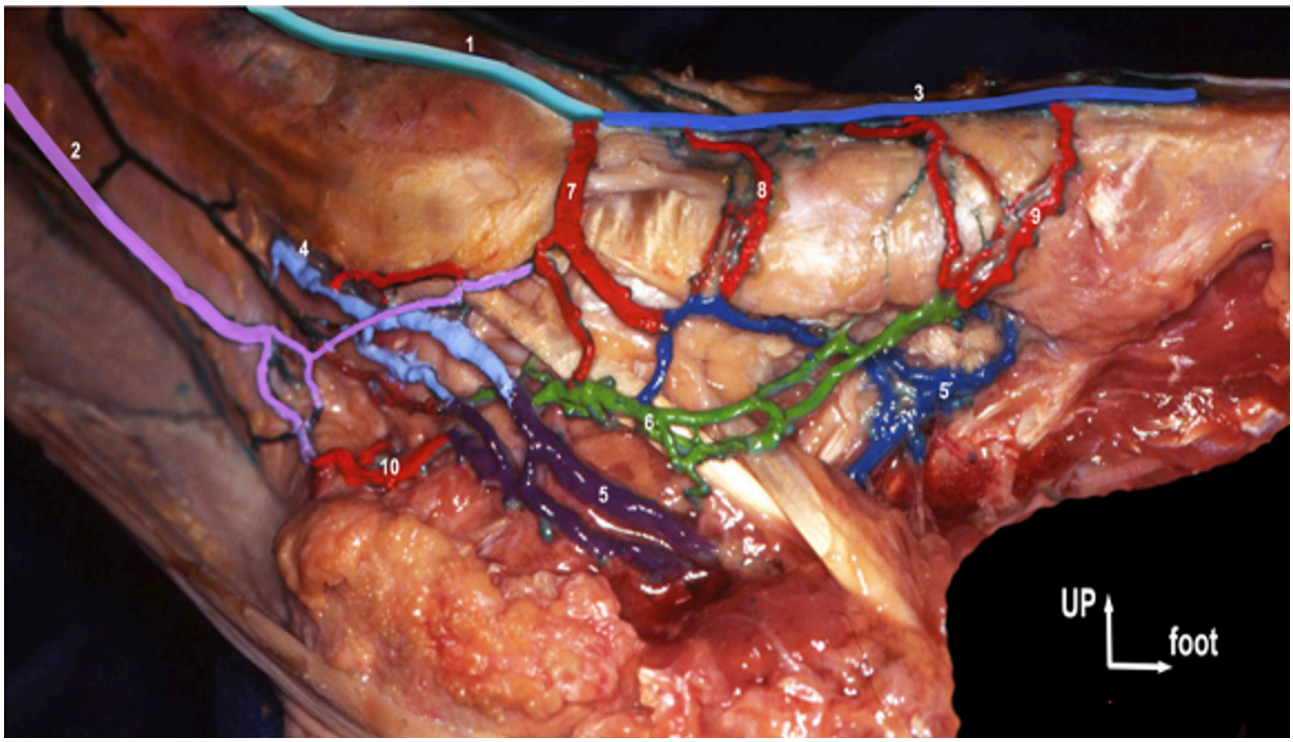

Figure 6B - Anatomical Dissection of the foot pump. (medial view of a left foot) 1= GSV 2= SSV 3= medial marginal vein 4= PT veins 5= lateral plantar veins 6= medial plantar veins 7= inframalleolar PV 8= navicular PV 9= Cuneal PV 10= calcanean PV

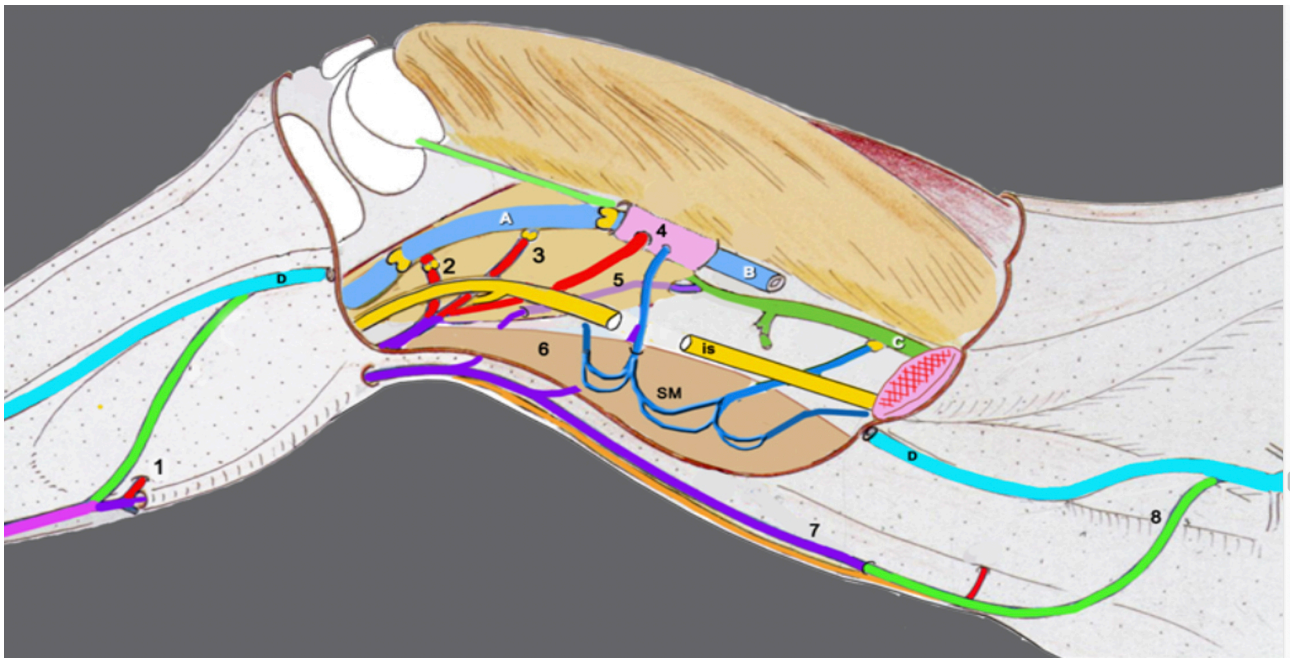

Figure 7 - Types of SSV termination. 1= SSV ends at mid calf, into the posterior circumflex of the leg and/or the intergemellar perforator 2= Standard SPJ anatomical location 3= High SPJ 4= Draining into femoral vein through Hunter's canal 5= Draining into Deep femoral vein through biceps muscle 6= Draining into venous arches of the semimembranosus muscle (SM) 7= Thigh extension of the SSV 8= Giacomini vein is= Sciatic nerve.

4. Results with examples of selected chapters

Richly illustrated through numerous clinical cases, it helps the reader to elucidate the complexity of venous disease related to the great anatomical variability of the system.

a/ Venous system of the **lower limbs and pelvis**.
The outstanding iconography of this book includes 619 original color diagrams, 866 diagnostic images and 85 clinical photographs. It is a must tool to improve the insight on ultrasound assessment of the venous system.
This book offers an innovative guide for sonographers and surgeons dedicated to the venous network, allowing them to predict reflux pathways and thus refine their diagnostic accuracy in daily practice. A must for the venous mapping.
We will see 3 examples:

- Foot perforators[37] and foot pump anatomy[38] locations. (figure 6 below)
The foot veins should not be distinguished into deep and superficial, but into medial unit (GSV, medial PVs and medial plantar veins) and lateral unit (SSV, lateral PVs and lateral plantar veins)
- Main types of SSV termination[39,40].
The small saphenous vein termination is highly variable as shown figure 5. This is related to its embryogenesis, being an anastomosis between the posterior plexus and the axial plexus, as explained in the embryo chapter.
- Pelvic veins: Gluteal inferior (Gi) pelvic leak point and varix of the ischiatic nerve (figure 6)

b/ Venous system of **abdomen and thorax**.
Two examples of interesting topics:

I- Anatomy of the left renal vein tributaries[41-45] (drawing figure 9 and 3d modeling figure 10)[46]
II- Left external iliac vein thrombosis with May Thurner syndrome[47-49] (figure 11)

c/ Veins of the head and neck and of the upper limbs.
Among the chapters, the example of 2 dissections of upper limb's veins (Figure 12).

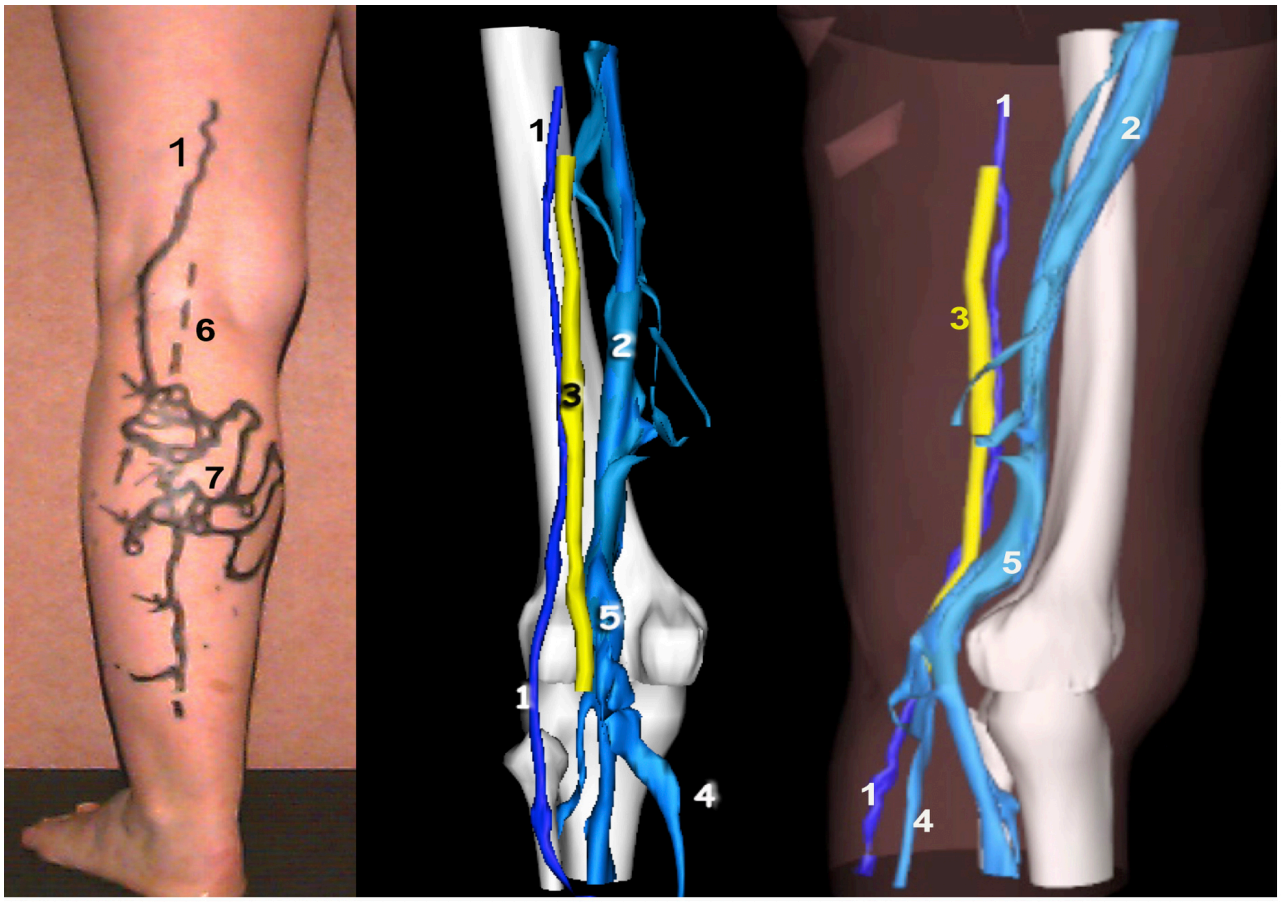

Figure 8 - Gluteal inferior point. Pelvic reflux through the inferior gluteal vein feeds sciatic nerve sheath´s varicosis (1). Following the path of the sciatic nerve (3), common peroneal nerve and its branch (lateral sural cutaneous nerve), deep reflux becomes superficial (lateral to midline, above the knee joint line) to finally feed a varicose network of the calf (7). Despite the regional distribution of varices, both the SSV trunk (6) and the SPJ are competent. 2= femoral vein 4= medial gastrocnemius vein 5= popliteal vein .

References

1) Uhl JF. Focus on embryogenesis of the venous system of the lower limbs. Phlebolymphology 2015;22(2):55-62

2) Uhl JF, Gillot C. Embryology and three-dimensional anatomy of the superficial venous system of the lower limbs. Phlebology 2007;22(5):194-206

3) Uhl JF, Gillot C, Chahim M. Anatomical variations of the femoral vein. J Vasc Surg. 2010 Sep;52(3):714-9.

4) Uhl JF, Gillot C. Anatomy of the foot venous pump: Physiology and influence on chronic venous disease. Phlebology 2012,27:219-30.

5) Uhl JF, Verdeille S, Martin-Bouyer Y. 3D CT venography for the pre-operative assessment of varicose patients VASA 2003;32(2):91-94.

6) Uhl JF, Verdeille S, Martin-Bouyer Y. Pre-operative assessment of varicose patients by veno-CT with 3D reconstruction. 3rd International workshop on multislice CT 3D imaging Springer Verlag Ed pavone, Debatin (2003) p 51-53.

7) Uhl JF and Caggiati A. Multidetector-Row CT Angiography : Three-Dimensional Evaluation of the Venous System in Varicose Limbs by Multidetector Spiral CT. Medical Radiology, 2005, 199-206 (Springer)

8) Uhl JF, Chahim M, Verdeille S, Martin-bouyer Y. The 3D modeling of the venous system by MSCT venography (CTV): technique, indications and results Phlebology 2012;27:270–88.

9) Uhl JF, Guillermo Prat, David Costi, José Alberto Ovelar, Franco Scarpelli, Camilo Ruiz, Bárbara Lorea. Modelado 3D del sistema vascular. Flebología 2018;44:17-27.

10) Uhl JF, Chahim M, Cros F, Ouchene A. 3D modelling of the vascular system. J of Theoretical and Applied Vascular Research – JTAVR 2016;1(1):51-8.

11) Min SK, Kim SY, Park YJ, Lee W, Jung IM, Lee T, Ha J, Kim SJ. Role of three-dimensional computed tomography venography as a powerful navigator for varicose vein surgery. J Vasc Surg 2010;51(4):893-9.

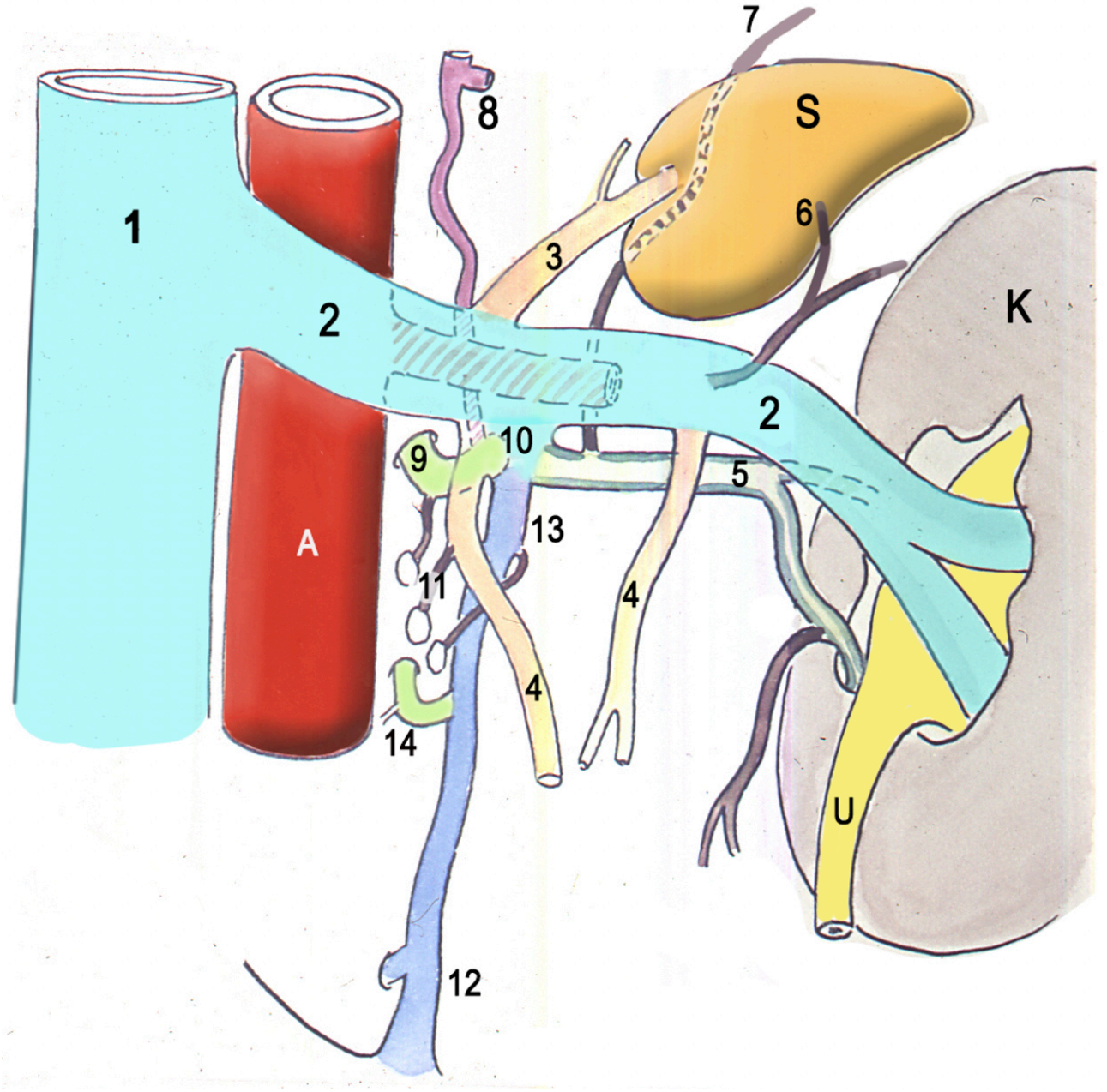

Figure 9 - Tributaries of the left renal vein (LRV) drawing from a dissection 1=IVC 2= LRV 3= Main left suprarenal vein 4= Left gonadal vein 5= Posterior renal vein (retro-pylelic) 6= Inferior suprarenal vein 7= Inferior diaphragmatic vein 8= Medial root of hemiazygos vein 9= Intrapsoic vein 10= Arch of Lejars 11= Small collaterals (nodes) 12=Left iliolumbar vein 13= ALV 14= Lumbar veins at L2 Aorta (A) K= Left kidney S= Suprarenal gland (in orange) U= Left ureter.

12) Whal Lee et al. 3-Dimensional CT Venography Adequately Visualizes Lower Limb Varicosities Am J Roentgenol 2008;191:1186-91

13) Fraser D.G.W, Moody AR, Davidson IR, Martel AR, Morgan PS. Deep venous thrombosis: venous enhanced subtracted peak arterial MR venography versus conventionnal venography for diagnosis. Radiology 2003;226:810-20.

14) Fujikawa A, Matsuoka S, Kuramochi K, Yoshikawa T, Yagihashi K, Kurihara Y,Nakajima Y. Vascular enhancement and image quality of CT venography: comparison of standard and low kilovoltage settings. AJR Am J Roentgenol. 2011 Oct;197(4):838-43.

15) Oda S, Utsunomiya D, Awai K, Takaoka H, Nakaura T, Katahira K, Morishita S, Namimoto T, Yamashita Y. Indirect computed tomography venography with a low-tube-voltage technique:reduction in the radiation and contrast material dose -a prospective randomized study. J Comput Assist Tomogr. 2011 Sep-Oct;35(5):631-6.

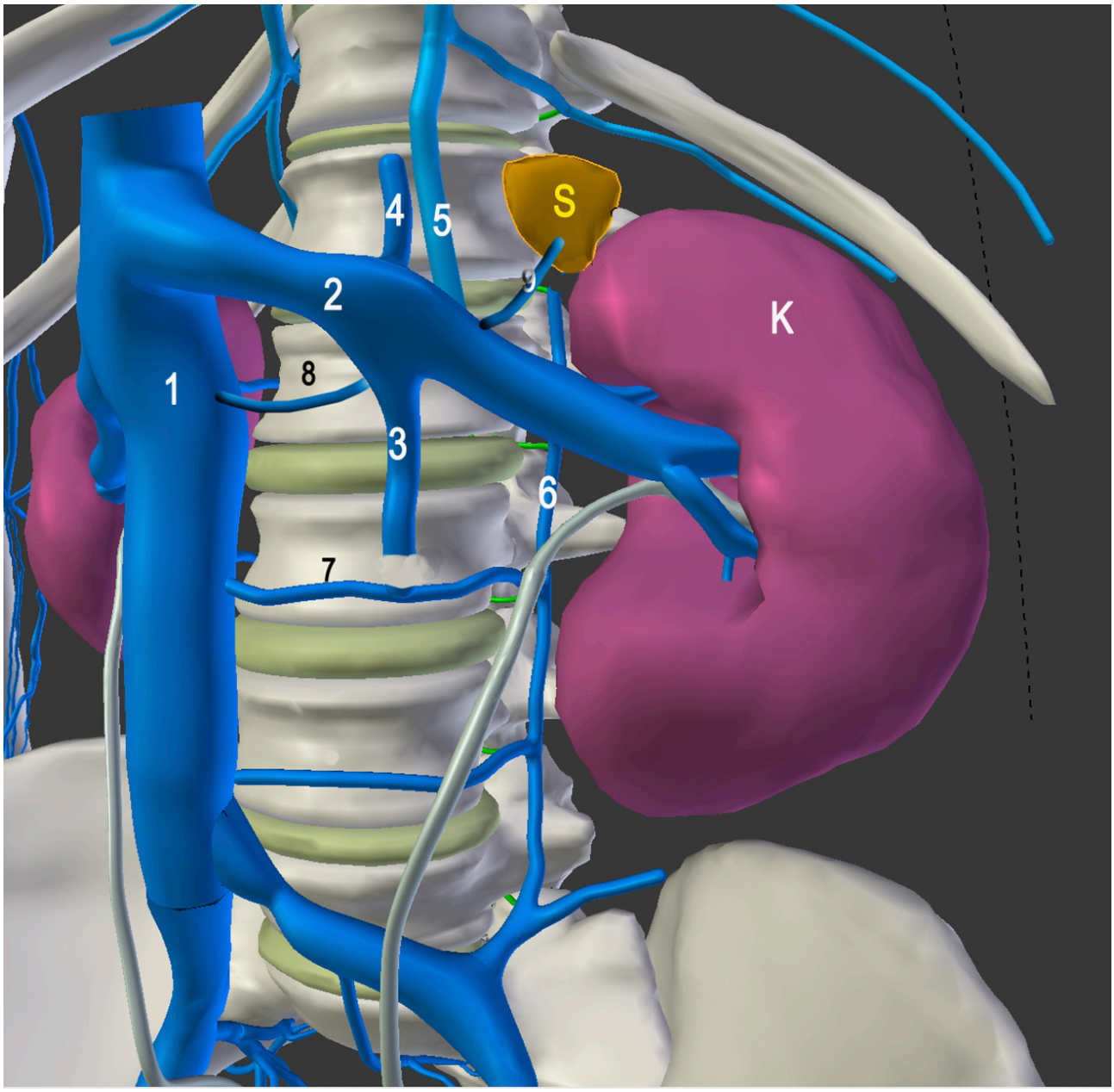

Figure 10 - 3D modeling of the Left renal vein and tributaries (from Diva3D® table) 1=IVC 2= LRV 3= Left gonadal vein 4= Inferior diaphragmatic vein 5= Medial root of hemiazygos 6= Ascending lumbar vein (ALV) 7= Lumbar vein at L2 8= Lumbar vein at L1 9= Left suprarenal vein K= Left kidney S= Suprarenal gland. Please notice the narrowing of the LCIV (may-Thurner syndrome).

16) Nakaura T, Awai K, Oda S, Yanaga Y, Namimoto T, Harada K, Uemura S, Yamashita Y. A low-kilovolt (peak) high-tube current technique improves venous enhancement and reduces the radiation dose at indirect multidetector-row CT venography: initial experience. J Comput Assist Tomogr. 2011 Jan-Feb;35(1):141-7.

17) Hori Y, Yoshimura N, Horii Y, Takano. Multidetector computed tomography venography: optimum dose of contrast material. Jpn J Radiol. 2010 Jun;28(5):335-9.

18) Abdelmoumene Y, Chevallier P, Barghouth G. et al. Optimization of Multidetector CT Venography Performed with Elastic Stockings on Patients' Lower Extremities: A Preliminary Study of Nonthrombosed Veins. AM J ROENTGENOL 2003; 180:1093-4.

19) Caggiati A, Ricci S, Laghi A, Luccichenti G, Pavone P. 3D contrastless varicography by spiral computed tomography. Eur. J. Vasc. Endovasc Surg. 2001 Apr;21(4):374-6.

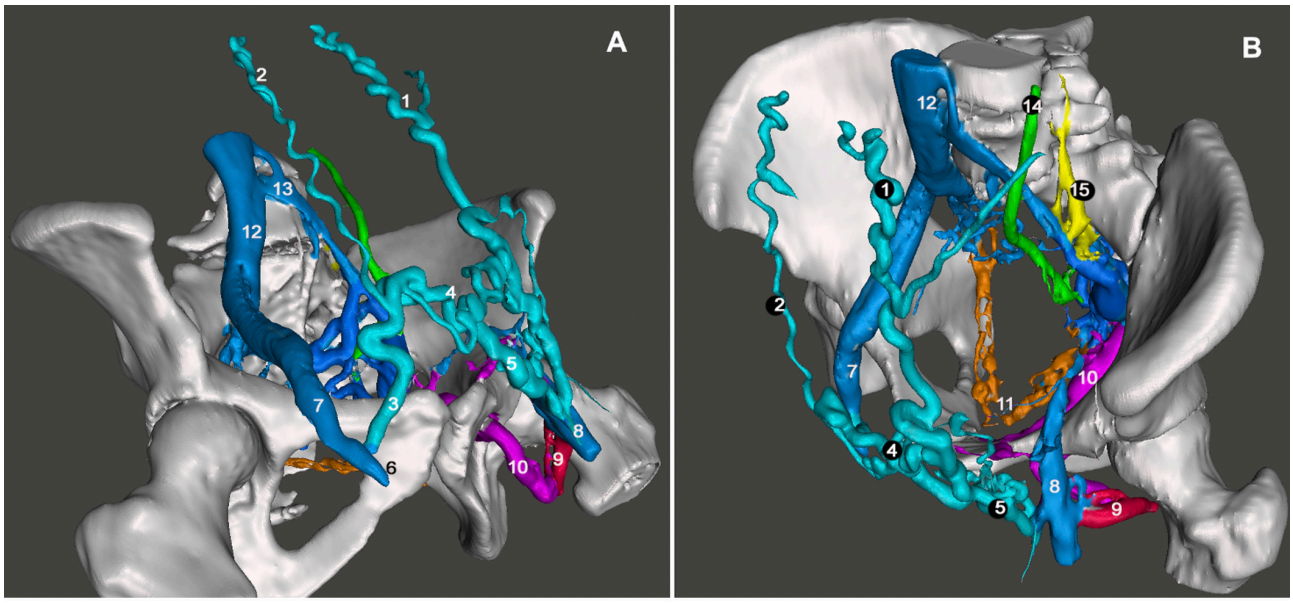

Figure 11 - Left iliac thrombosis (CT-Venography with reconstruction by surface rendering) A: right inferior view. B: left superior view 1= Left superficial epigastric vein 2= Right superficial epigastric vein 3= Right external pudendal vein 4= Suprapubic anastomosis (Palma) 5= Left external pudendal vein 6= Right GSV 7= Right FV 8= Left FV 9= Left medial circumflex vein (in red) 10= Left obturator vein (in purple) 11= Vesical veins (orange) 12= IVC 13= LCIV compressed with synecia (MTS) 14= Left ovaric vein (green) 15= Left iliolumbar vein (yellow).

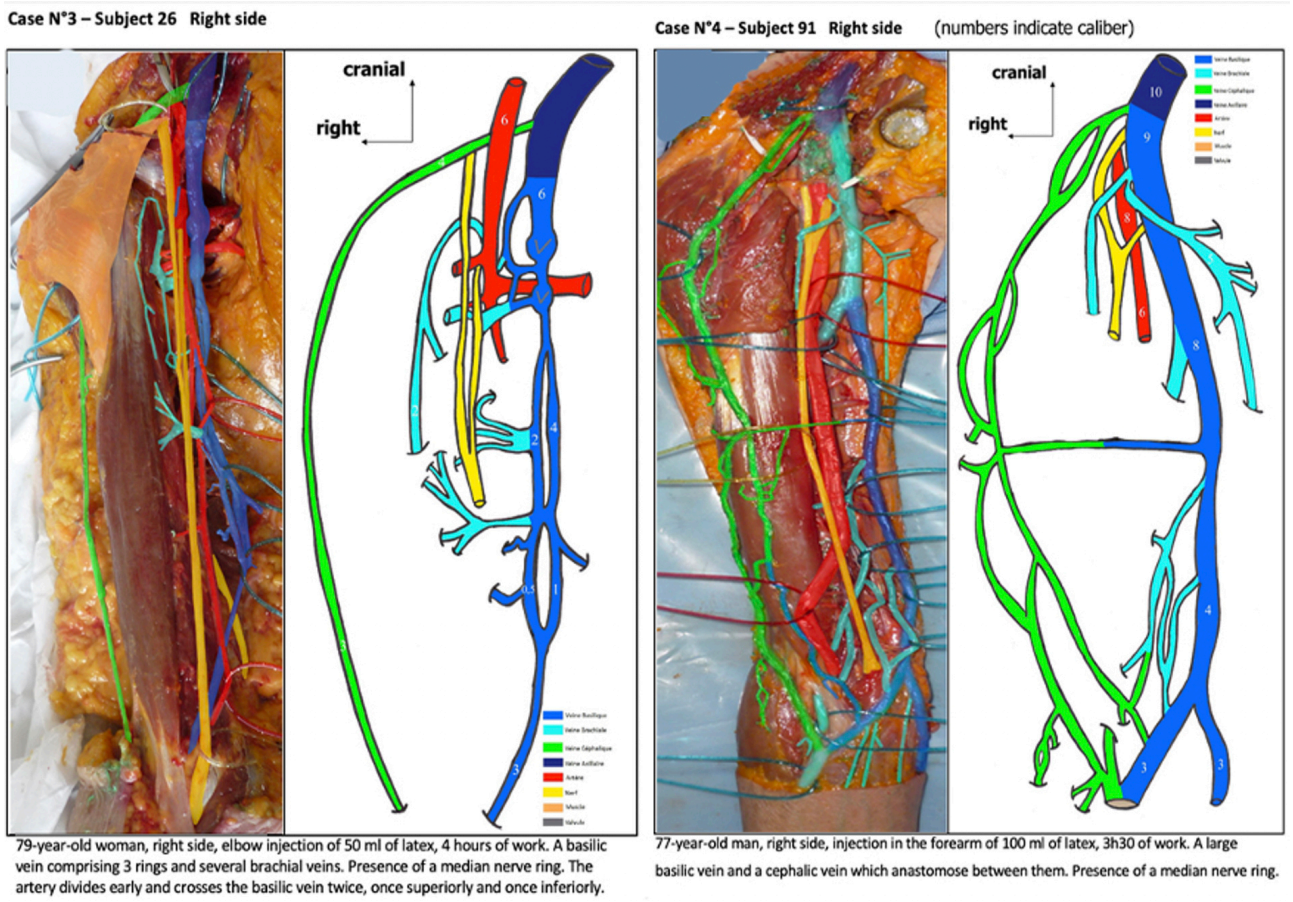

Figure 12 - Systematization of the upper limb's veins (unpublished).

20) Kim SY, Park EA, Shin YC, Min SI, Lee W, Ha J, Kim SJ, Min SK. Preoperative determination of anatomic variations of the small saphenous vein for varicose vein surgery by three-dimensional computed tomography venography. Phlebology. 2012 Aug;27(5):235-41. doi: 10.1258/phleb.2011.011023. Epub 2011 Oct 28. PMID: 22037280.

21) Jung SC, Lee W, Chung JW, Jae HJ, Park EA, Jin KN, Shin CI, Park JH Unusual causes of varicose veins in the lower extremities: CT venographic and Doppler US findings. Radiographics 2009 Mar-Apr;29(2):525-36.

22) Jeon UB, Chung JW, Jae HJ, Kim HC, Kim SJ, Ha J, Park JH. May-Thurner syndrome complicated by acute iliofemoral vein thrombosis: CT venography for evaluation of long-term stent patency and changes in the iliac vein. AJR Am J Roentgenol. 2010 Sep;195(3):751-7.

23) Kim KW, Cho JY, Kim SH, Yoon JH, Kim DS, Chung JW, Park JH. Diagnostic value of computed tomographic findings of nutcracker syndrome: correlation with renal venography and renocaval pressure gradients. Eur J Radiol. 2011 Dec;80(3):648-54.

24) Mavili E, Ozturk M. et al. Direct CT venography for evaluation of the lower extremity venous anomalies of Klippel-Trenaunay syndrome AJR 2009;192:311–6.

25) Park EA, Chung JW, Lee W, Yin YH, Ha J, Kim SJ, Park JH. Three-dimensional evaluation of the anatomic variations of the femoral vein and popliteal vein in relation to the accompanying artery by using CT venography. Korean J Radiol. 2011 May-Jun;12(3):327-40.

26) Goodman L.R, Stein P. D, Matta F. and al. CT Venography and Compression Sonography Are Diagnostically Equivalent: Data from Pioped II. AM J Roentgenol 2007;189:1071-6.

27) Duwe K.M, Shiau M, Budorick N.E , Austin J.H.M, Berkmen Y.M Evaluation of the Lower Extremity Veins in Patients with Suspected Pulmonary Embolism: A Retrospective Comparison of Helical CT Venography and Sonography. AM J Roentgenol 2000;175:1525–31.

28) Begemann PG, Bonacker M, Kemper J, et al. Evaluation of the deep venous system in patients with multi-detector CT: a prospective study in comparison to Doppler sonography. J Comput Assist Tomogr 2003;27:399-409.

29) Yoshida S, Akiba H, Tamakawa M, Yama N, Takeda M, Hareyama M. Spiral CT venography of the lower extremities by injection via an arm vein in patients with leg swelling. Br J Radiol 2001;74:1013-6.

30) Gaweesh AS, Kayed MH, Gaweesh TY, Shalhoub J, Davies AH, Khamis HM Underlying Deep Venous Abnormalities in Patients with Unilateral Chronic Venous Disease - A Pilot Study Using Direct Injection CT Venography. Phlebology 2013;28:426–43.

31) Chung JW, Yoon CJ, Jung SI, Kim HC, Lee W, Kim YI, et al. Acute iliofemoral deep vein thrombosis: evaluation of underlying anatomic abnormalities by spiral CT venography. J Vasc Interv Radiol 2004 Mar;15(3):249-56.

32) Lee W, Chung J.W, Yong Hu Yin, and al. 3D CT Venography of Varicose Veins of the Lower Extremity: Image Quality and Comparison with Doppler Sonography. AM J Roentgenol 2008 Oct;191(4):1186-91.

33) Ghaye B, Szapiro D, Willems V, Dondelinger RF Pitfalls in CT venography of lower limbs and abdominal veins. AM J Roentgenol 2002;178:1465-71.

34) last accessed on Feb 8th, 2024 https://www.slicer.org/

35) last accessed on Feb 8th, 2024 www.meshmixer.com

36) last accessed on Feb 8th, 2024 https://builder3dprinters.com/software/

37) Uhl JF, Miguel Lo Vuolo and C. Gillot. Anatomy of the perforator veins of the foot and ankle. Phlebolymphology 2017;24(2):105-12.

38) Uhl J-F, Gillot C. The foot venous pump. Anatomy and physiology. Phlebolymphology 2010;17:151–8.

39) JF Uhl and Claude Gillot Anatomy and embryology of the small saphenous vein: nerve relationships and implications for treatment. Phlebology. 2013 Feb;28(1):4-15.

40) JF Uhl, C. Gillot , P. Lemasle Relationship between the short saphenous vein and nerves: implications for the management of chronic venous disease. Phlebolymphology. 2006;13:22-27.

41) Gillot C: La veine rénale gauche. [The left renal vein] Anatomia Clinica 1978;1:135–155.

42) Gillot C, Gallegos Monroy AA, Aaron C. L'anatomie chirurgicale de la veine re#nale gauche. [Surgical anatomy of the left renal vein] J. Chir. Paris 1967;93(4):447-60.

43) Lejars F. Les voies de sûreté de la veine rénale. Bull Soc Anat (Paris) 63éme Année, 5ème Série:504–511, 1888a.

44) Satyapal KS. Classification of the drainage patterns of the renal veins. J. Anat. 1995;186:329-333.

45) Gupta A, Gupta R, Singal R. Congenital Variations of Renal Veins: Embryological Background And Clinical Implications. Journal of Clinical and Diagnostic Research. 2011 November (Suppl-1);5(6):1140-3.

46) 3D atlas of the human body. Chapter 6 pages 103-120 from Springer book of Digital anatomy: Applications of Virtual, Mixed and Augmented Reality. May 2021 (https://www.springer.com/gb/book/9783030619046) Editors Uhl JF, Simoes D, Jorge J.

47) May R, Thurner J. The cause of predominantly sinistral occurrence of thrombosis of the pelvic veins. Angiology 1957;8:419–427.

48) Cockett FB, Thomas Lea M. The iliac compression syndrome. Br J Surg 1965;52:816-21.

49) Peters M, Khazi Syed R, Katz M, Moscona J, Press C,Niijar V, Bisharat M, Baldwin D. May-Thurner syndrome: a not so uncommon cause of a common condition. Baylor Universitiy Medical Center 2012 Jul;25(3):231-3.